

Letter to editor

Orbital Cysticercosis – masquerading as preseptal cellulitis with ptosis

Amit Raj, Sudesh Kumar Arya, Pratik Topiwala, Panchmi Gupta, Sunandan Sood
Government Medical College & Hospital, Chandigarh, India

Dear Editor,

We are sharing a case of orbital cysticercosis, which presented to us initially with simple ptosis and later on with upper lid inflammation and restricted ocular motility in upgaze. Human cysticercosis, a parasitic infection caused by *Cysticercus cellulosae*, the larval form of the cestode, *Taenia solium*, is a benign infection of the subcutaneous tissues, inter-muscular fascia, muscles and other organs. Though it exists worldwide, it is more prevalent in the developing countries of Latin America, Asia and Africa, especially in areas where under-cooked pork is consumed regularly (Pushker et al, 2001). However, 5 year study of 33 cases of Ocular/Adnexal cysticercosis showed seventy percent of patients were of low socioeconomic group and 70% were strictly vegetarians (Atul et al, 1995). The clinical manifestation of orbital cysticercosis is entirely different from neuro-cysticercosis or cysticercosis of other parts of body. Diagnosis of cysticercosis is mainly based on highly specific radiological signs and history of exposure in endemic areas.

A twenty eight year old female presented to our oculoplastic clinic with progressively increasing ptosis of right upper eyelid since last ten days. On presentation, a complete ptosis work up was done and she was diagnosed as a case of congenital ptosis and she was asked to return with her previous photographs. She returned again five days later with complaints of right upper eyelid swelling which was painful and was associated with ecchymosis of overlying skin. Her previous photographs did not show ptosis in either of the eye. On ocular examination, she had a snellen visual acuity of 20/20 in both eyes. The left eye was essentially normal. Adnexal examination revealed the presence of right tender upper eyelid swelling with the overlying skin being hyperaemic and local temperature was also raised. The extraocular movements were restricted in upgaze and was painful. Therefore, a presumptive diagnosis of right upper lid preseptal cellulitis with ptosis was made and was started on intravenous antibiotics of standard regimen.

Patient was advised to get CT Scan Orbit, but patient could not afford the same. Her blood investigations were sent and total leukocyte count was raised and eosinophilia ($456/\text{mm}^3$) was present.

Address for correspondence
Dr Amit Raj
Email id- rajdoc78@yahoo.com
Tel: +91-9646741005

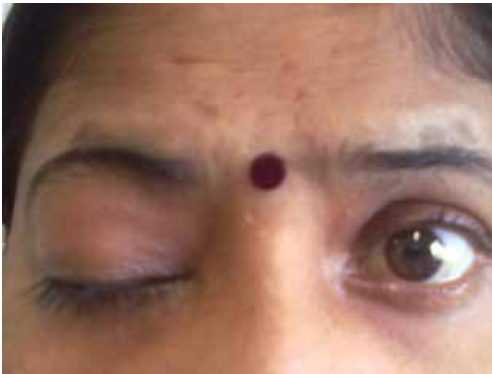After 5 days of intravenous antibiotics, the swelling of the eyelid decreased and the extraocular movement in upgaze improved, but her ptosis did not improve. An USG B Scan of the right eye also showed a small cystic lesion measuring 5×6 mm superior to the eyeball. Now, again CT Scan Orbit with Brain was advised, it was done from hospital fund. The CT Scan revealed the presence of two well defined ring enhancing lesions of 5.2 × 6.5 mm ,with an eccentric spec abutting the right superior rectus muscle. The muscle was also seen to be bulky adjoining the lesion. The other eye was normal and there was no intracranial focal lesion. Keeping in mind these findings, a final diagnosis of right orbital cysticercosis involving the right superior rectus was made. The patient belonged to a rural background and worked in the fields regularly.

After ruling out intra-ocular cysticercosis, patient was started on high dose steroid therapy (Tab. Prednisolone 1.5mg/kg body weight) and 3 days later oral anti helminthic drug (Albendazole 15mg/kg body weight in two divided doses daily) was added. After one month of therapy , the ptosis markedly improved, with complete recovery of restriction in upgaze.

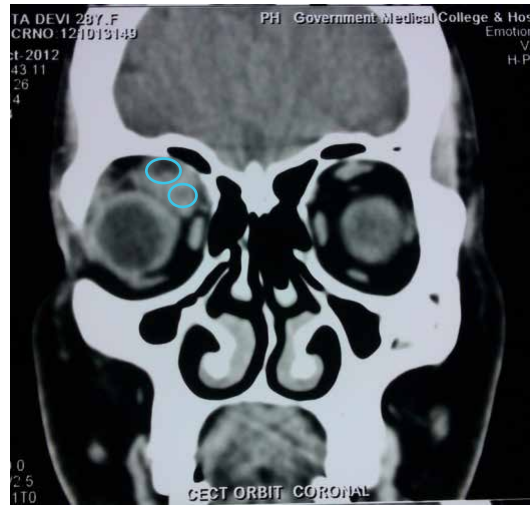
In India, the cysticercus cysts are more often found in the subconjunctival space whereas in western countries, the posterior segment is more affected(Park et al, 2011). Orbital cysts are rare, and amongst them the extraocular muscle form is the most common type(Pushker et al, 2001). Review of available literature shows that medial rectus is the most commonly involved muscle in myocysticercosis (42%), followed by superior rectus(18%), lateral rectus(15%), inferior rectus (13%), superior oblique(5%), levator palpebrae superioris (5%) and inferior oblique (1%)(Pushker et al, 2001).

High resolution ultrasonography, CT scan and MRI can detect the cyst with the scolex, with USG being better in picking up the scolex(Pushker et al, 2001). Eosinophilia, as seen in our patient has been reportedly seen in 71% patients with ocular cysticercosis(Singh, 1993). Tissue diagnosis is not essential for initiating therapy(Pushker et al, 2001). After ruling out neurocysticercosis and intraocular cysticercosis, medical therapy with albendazole (15 mg/kg per day in two divided doses) and oral steroids (1.5-2mg/kg per day) for four weeks is given for orbital cysticercosis(Bhalla et al, 2008)who had involvement of the brain, subcutaneous tissues, skeletal muscles, right orbit and thyroid gland. In addition, this patient developed a serum sickness which responded to therapy.\n\nConclusion\nWide spread dissemination is a rare complication of cysticercosis. A planned approach to therapy is required.

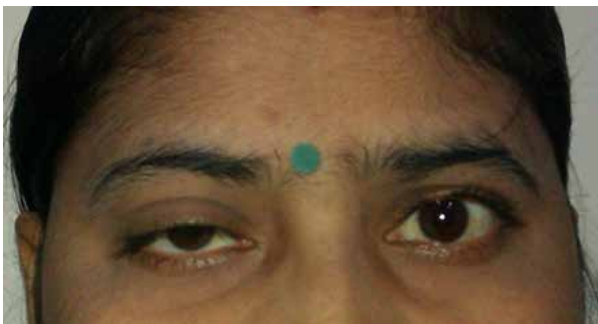Our patient presented with preseptal cellulitis and ptosis which is an extremely unusual presentation for myocysticercosis. Only after CT scan, a diagnosis of orbital cysticercosis could be made. After starting the patient on oral anti helminthic and steroid, her ptosis improved with ocular motility also becoming better. Our patient demonstrates that cysticercosis should be suspected in patients with acquired unilateral ptosis with restricted ocular motility, especially young patients living in endemic areas.



Presentation 5 days after IV antibiotics



Coronal CT view showing the presence of two well defined ring enhancing lesions with eccentric spec abutting the right superior rectus muscle



Status post One month steroid and antihelminthic therapy

References

- Bhalla A, Sood A, Sachdev A, Varma V (2008). Disseminated cysticercosis: a case report and review of the literature. *J Med Case Reports*; 2: 137.
- Park SY, Kong MH, Kim JH, Song KY (2011). Disseminated cysticercosis. *J Korean Neurosurg. Soc*; 49: 190–193.
- Pushker N, Bajaj MS, Chandra M, Neena (2001). Ocular and orbital cysticercosis. *Acta Ophthalmol Scand*; 79: 408–413.
- Sekhar GC, Lemke BN (1997). Orbital cysticercosis. *Ophthalmology*; 104: 1599–1604.
- Singh RY (1993). Sub-conjunctival *Cysticercus cellulosae*. *Indian J Ophthalmol*; 41: 188–189.
- Atul K, Kumar TH, Mallika G, Sandip M(1995). Socio demographic trends in ocular cysticercosis. *Acta Ophthalmol Scand*; 73(5):438-41

Source of support: nil. Conflict of interest: none