

## Case report

# Post-traumatic endophthalmitis with retained intraocular foreign body – a case report with review of literature

Aggarwal P<sup>1</sup>, Garg P<sup>1</sup>, Sidhu HK<sup>1</sup>, Mehta S<sup>2</sup>

<sup>1</sup>Department of Ophthalmology, <sup>2</sup>Department of Microbiology  
Maharishi Markandeshwar Institute of Medical Sciences And Research, Mullana  
Ambala, Haryana, India

## Abstract

**Introduction:** Endophthalmitis following penetrating eye injuries has a poor prognosis and presents a diagnostic and therapeutic challenge. The aim of reporting this case was to identify the causative organism of post-traumatic endophthalmitis due to retained iron foreign body and to highlight the importance of carrying out diagnostic investigations. **Case:** A 20-year-old male presented with tenderness and blurring in the right eye 3 days after injury with an iron particle. Visual acuity was perception of light with accurate projection of rays in all quadrants. The slit-lamp examination revealed ciliary and conjunctival congestion. There was a vertically-oriented self-sealed, full-thickness laceration in the cornea adjacent to the limbus. The anterior chamber evaluation revealed + 4 cells, +3 flare and a 2 - mm hypopyon. There was cataract with a ruptured anterior lens capsule. Posterior synechiae was present at 5'0 clock position. B-scan showed echogenic metallic foreign body in the posterior chamber, with vitreous opacities. The vitreous tap was done and intra-vitreous antibiotics injections of 1 mg in 0.1 ml vancomycin and 2.25 mg in 0.1 ml ceftazidime were given. Culture and sensitivity of the tap revealed staphylococcus as the causative agent. The patient was put on moxifloxacin eye drops, fortified tobramycin and cephazolin eye drops 1 hourly along with atropine eye drops. The patient was referred to the vitreoretinal surgeon urgently for pars plana vitrectomy and foreign body removal. At follow up, the patient's BCVA was improved. **Conclusion:** The causative organism isolated was similar to that documented in other reports. Endophthalmitis must be treated with vitrectomy and intra-vitreous injections of antibiotics after a proper vitreous tap.

**Key-words:** vitreous tap, intravitreal injection, post-traumatic endophthalmitis, pars plana vitrectomy, retained intra-ocular foreign body

## Introduction

Post-traumatic endophthalmitis makes up a distinct subset of intraocular infections. It is an uncommon but potentially devastating complication of penetrat-

ing ocular injuries especially with retained intraocular foreign bodies (IOFBs) with poor prognosis. Eyes with Retained IOFBs are more likely to develop endophthalmitis than those with penetrating injuries with no foreign bodies, in approximately 5 to 13% of cases causing a poor final visual outcome (Williams et al, 1983; Brinton et al, 1984; Thompson et al, 1993). The virulent organisms com-

Received on: 20.07.2011

Accepted on: 20.11.2011

**Address for correspondence:** Dr Parul Aggarwal, MS, Assistant Professor, Department Of Ophthalmology, Maharishi Markandeshwar Institute of Medical Sciences and Research, 10-A Bhupindra Nagar Patiala, Mullana, Ambala, Haryana, India  
Tel: +91-9996396162, Fax:+91-1642211567  
E-mail: doc\_parul82@yahoo.com

monly isolated are Gram-positive bacteria, *Streptococcus*, *Enterococcus* and *Bacillus cereus* with mixed infections not being uncommon (Affeldt et al, 1987; Kuan et al, 2009). Among this group, cases of endophthalmitis related to injuries taking place in rural areas are especially severe and issue of concern. It requires skillful investigation and an early intervention.

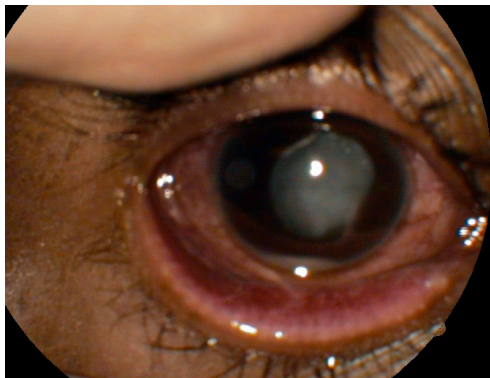
Pars Plana Vitrectomy, which may reduce the incidence and the severity of endophthalmitis is suggested for the treatment of retained IOFBs and its complications (Affeldt et al, 1987). Intravitreal antibiotics are must in patients with a positive culture in cases of endophthalmitis.

The purpose of reporting this case was to identify the causative organism and to highlight the importance of carrying out diagnostic investigations like B-Scan in every patient of penetrating intraocular injury as it can completely change the diagnosis, management and visual prognosis.

### Case report

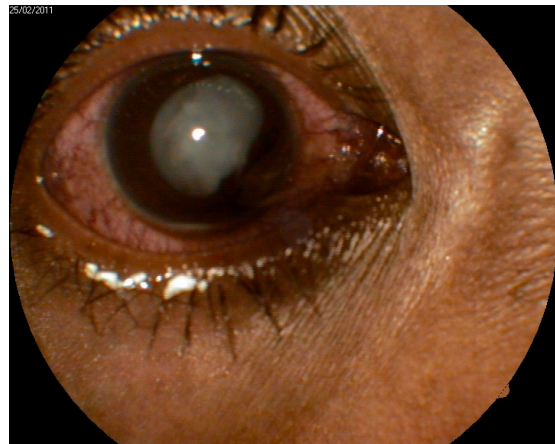
A 20-year old male presented in the department of ophthalmology with pain and blurring in right eye, 3 days after injury with iron particle, while working in an iron factory. VA at initial presentation was PL+ve with PR accurate in all quadrants. The slit-lamp examination revealed circum-corneal and conjunctival congestion. Cornea showed a vertically oriented self-sealed full thickness laceration adjacent to limbus in the nasal half of the cornea. Anterior chamber showed +4 cells, +3 flare and 2mm hypopyon (Figure 1).

**Figure 1: Hypopyon**



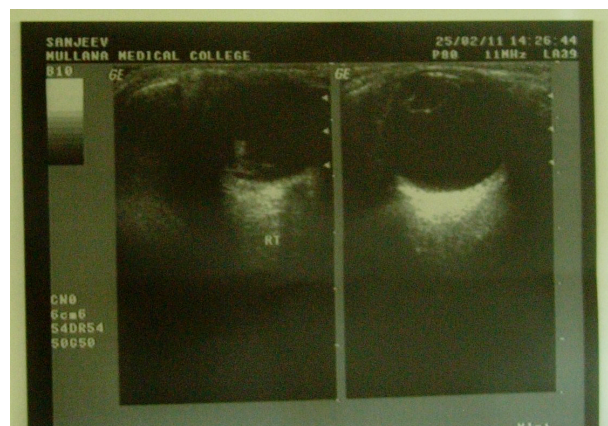
There was rupture of anterior lens capsule with formation of traumatic cataract. The fluffy cortex was coming out into AC. Posterior synechiae were present at 5 o' clock position with IOP 25 mm of Hg (Figure 2).

**Figure 2: Posterior synechiae**



B-scan was done to evaluate the posterior segment of the eye. It showed echogenic metallic foreign body in the posterior chamber with dense vitreous opacities and vitreous detachment and there was no evidence of retinal detachment (Figure 3).

**Figure 3: Echogenic vitreous opacities**



A clinical diagnosis of penetrating eye injury with traumatic endophthalmitis was made. The vitreous tap was done and an intra-vitreous antibiotics injection of 1 mg /0.1 ml vancomycin and 2.25 mg/0.1 ml ceftazidime was given. The vitreous tap was subjected to microbiological evaluation for culture and sensitivity. The patient was put on topical moxifloxacin eye drops, 133 mg/ml fortified cefazolin

with 14 mg/ml fortified tobramycin eye drops one hourly. Along with it, Prednisolone 1% eye drops 4 hourly and atropine eye drops were added to reduce the inflammation. Culture report showed Gram positive, coagulase -ve Staphylococcus (Figure 4).

**Figure 4: Coagulase -ve Staphylococcus**



The patient was referred to vitreoretinal surgeon for immediate Pars plana vitrectomy of the right eye with removal of retained intraocular foreign body. The patient reported after 2 weeks of vitrectomy and showed improvement in vision.

### Discussion

Endophthalmitis refers to the inflammatory process that involves the ocular cavity and adjacent structures. Traumatic endophthalmitis following penetrating eye injuries has a relative poor prognosis. This is due to the underlying eye trauma and the causation by more virulent bacteria as well as the attendant delay in diagnosis and treatment. These cases present difficult diagnostic and management issues, distinct from endophthalmitis postoperatively because of the co-existing ocular trauma. The present case also presented with delayed initial check-up resulting in a flared-up response.

According to Singh et al (2005), development of endophthalmitis correlated with younger age, rural setting, illiteracy, presence of foreign body and lens disruption, as was seen in this case (Williams et al, 1983; Thompson et al, 1993 ; Thompson et al, 1995; Schmidseider et al, 1998). The young age,

illiteracy and rural status are probably partly responsible for delayed presentation and thus more risk of infection (Thompson et al, 1995); Reynolds and Flynn, 1997). The reason for the development of endophthalmitis after a penetrating globe injury is, in most cases, a bacterial infection, and the dominant bacterial strains are Bacillus, Staphylococcus, and Streptococcus. In the present case, symptoms of endophthalmitis were intense, and were attributed to staphylococcus strain of Gram positive bacteria. Other reported studies have also confirmed Gram positive organisms to be the most common causative organism in the post traumatic endophthalmitis.

The value of culture of vitreous and aqueous samples in diagnosis of infectious endophthalmitis is well established. For specific antibacterial treatment, isolation and identification of bacterial pathogens along with antibiotic susceptibility spectrum is essential. The present case was treated by intra-vitreous antibiotics injections of vancomycin and ceftazidime, resulting in decrease in level of hypopyon. A prompt and accurate etiological diagnosis of suspected endophthalmitis is essential for the appropriate and timely treatment which is central for a successful visual outcome. Ceftazidime provides effective coverage for Gram negative intraocular infections and vancomycin provides coverage for Gram positive organisms.

Gram positive endophthalmitis is present in 42-47% of cases, Gram negative endophthalmitis in 26-42% and fungal endophthalmitis in 13-17 % of cases. All these studies showed a low culture positivity (45 – 54 % ).

In our patient although it was a sealed corneal tear, but retained intraocular foreign body was detected on routine B-scan. So It is advisable to carry out appropriate radiological and ultrasonographic studies in all patients of penetrating injuries to assess the posterior segment of the eye and to rule out presence of retained intraocular foreign body.

Prompt evaluation and surgical removal of retained foreign body is therefore recommended. Vitrectomy



within hours of presentation removes retained intraocular foreign body which may be harboring infectious material and irrigating the eye with sterile solution, thereby potentially reducing infectious material within the eye (Yang et al, 2010).

Timely institution of appropriate therapy must be initiated to control the infections and thereby minimize the ocular morbidity. If they are not treated promptly, it may lead to sight threatening condition.

Clinical features associated with better visual acuity outcomes include better presenting visual acuity, culture of a non-virulent organism, lack of a retinal detachment, absence of clinical endophthalmitis, and shorter wound length (Douglas et al, 2003).

On the basis of our experience, we advise the patients especially of rural settings to be aware of untoward complications associated with retained intraocular foreign body and immediate reporting to the ophthalmologist is required. Carrying out Pars Plana vitrectomy early and taking samples for examination in order to determine the pathogen is indispensable for proper diagnosis and management. Removal of a retained intraocular foreign body within 24 hours of injury markedly reduces the risk of developing infectious endophthalmitis. 'For eye care, the sooner you do the best, the best you get.'

## References

Affeldt JC, Flynn HW Jr., Forster RK (1987). Microbial Endophthalmitis Resulting From Ocular Trauma. *Ophthalmology*; 94: 407–13.

Brinton GS, Topping TM, Hyndiuk RA, Aaberg TM, Reeser FH, Abrams GW (1984). Post traumatic Endophthalmitis. *Arch Ophthalmol*; 102: 547–50

Douglas FL, Scott IU, Flynn HW Jr., Darlene Miller, Feuer WJ (2003). Open Globe Injuries With Positive Intraocular Cultures: Factors Influencing Final Visual Acuity Outcomes. *Bottom*

of *FormOphthalmology*; 110(8):1560-66

Kuan-Jen Chen, Ko-Jen Yang, Chi-Chin Sun, Ling Yeung (2009). Traumatic endophthalmitis caused by *Enterococcus raffinosus* and *Enterobacter gergoviae*. *J Med Microbiol April*; vol. 58 (4):526-528

Reynolds DS, Flynn HW Jr (1997). Endophthalmitis After Penetrating Ocular Trauma. *Curr Opin Ophthalmol*; 8 (3): 32-8.

Schmidseder E, Mino De Kaspar H, Klauss V, Kampik A (1998). Post-Traumatic Endophthalmitis After Penetrating Eye Injuries. Risk Factors, Microbiological Diagnosis And Functional Outcome. *Ophthalmology*; 95 (3): 153-57

Singh DV, Sharma YR, Azad RV et al (2005). Profile of Ocular Trauma at Tertiary Eye Centre JK Science; 7 (1):1-6.

Thompson JT, Parver LM, Enger CL, Mieler WF, Liggett PE (1993). Infectious Endophthalmitis After Penetrating Injuries With Retained Intraocular Foreign Bodies. *National Eye Trauma System. Ophthalmology*; 100: 1468–74.

Thompson WS, Rubsamen PE, Flynn Jr Hw, Schiffman J, Cousins Sw (1995). Endophthalmitis After Penetrating Trauma: Risk Factors And Visual Acuity Outcomes. *Ophthalmology*; 102: 1696–1701.

Williams DF, Mieler WF, Abrams GW, Lewis H (1983). Results and Prognostic Factors In Penetrating Ocular Injuries With Retained Intraocular Foreign Bodies. *Ophthalmology*; 90: 1318–22.

Yang CS, Lu CK, Lee FL, Hsu WM, Lee YF, Lee SM (2010). Treatment And Outcome Of Traumatic Endophthalmitis In Open Globe Injury With Retained Intraocular Foreign Body. *Ophthalmologica*; 224(2): 79-85.

Source of support: nil. Conflict of interest: none