

Case report

Spontaneous rupture of lens capsule with dislocation of nucleus in hypermature cataract

VK Malik, Rishi Jhalani, KPS Malik, Abhishek Gupta,
Sanjiv Kumar, Rohit Kapoor and Charu Jain
Department of Ophthalmology, Subharti Institute of Medical Sciences,
Meerut (U.P), India

Abstract

We report a case of spontaneous rupture of the lens capsule in a woman with hypermature cataract, who presented to us with nucleus dislocation in the posterior chamber of her left eye. The capsule had ruptured inferiorly and the nucleus had slid out of it. The anterior chamber was quiet; and no sign of uveitis was noted. She underwent nucleus extraction and IOL implantation in the sulcus. Spontaneous rupture of the anterior lens capsule that leads to dislocation of the nucleus is a rare complication of hypermature cataracts.

Keywords: spontaneous dislocation, hypermature cataract

Introduction

A hypermature cataract occurs when the cortical lens fibers become liquefied and produce milky fluids. This condition leads to numerous potentially blinding conditions, including lens-induced uveitis, acute phacomorphic glaucoma, and phacolytic glaucoma. Spontaneous lens dislocation into the vitreous cavity (Bass LJ et al, 1985; Haymet BT, 1990) and absorption of the lens material (Uemura A et al, 1988; Mohan M et al, 1999) have been described as complications of hypermature cataracts.

We report a case of spontaneous rupture of the lens capsule in a woman with hypermature cataract, who presented to us with nucleus dislocation in the posterior chamber of her left eye. It is important to highlight this rare presentation because it may lead to potential errors in identifying causes of nucleus dislocation, especially when a history of trauma is absent.

Case report

A 50-year-old female came to us with the history of diminution of vision in her left eye for nine years. The right eye was pseudophakic and had undergone an operation ten years back. There was no history of recurrent eye redness or eye pain. She denied having a history of eye trauma or of wearing glasses.

On examination, the visual acuity in the left eye was 1/60. Her vision in the left eye with a +11 D spherical correction was 6/12. A slit-lamp examination revealed a clear cornea in the left eye. The nucleus was small and had been dislocated inferiorly into the posterior chamber of the left eye (Fig 3), just behind the iris. The capsule had ruptured inferiorly like an envelope (Fig 1) and the nucleus had slid out of it. The rolled-up edges of the capsule were visible and the posterior slit looked like an inverted question mark, as if challenging us to deduce as to when and how this had happened (Fig 2). Calcification spots on the capsule were clearly visible, suggesting they were from a ruptured, hypermature cataract which had resulted in the dislocation of nucleus. The anterior chamber was quiet, and no sign of uveitis was noted.

Received on: 12.11.2013

Accepted on: 25.11.2013

Address for correspondence

Dr VK Malik, Associate Professor
Department of Ophthalmology, Subharti Medical College
Haridwar Bypass Road, NH 58, Meerut 250005 (U.P)
Tel: 09837098211
Email: vkmalik55@yahoo.com

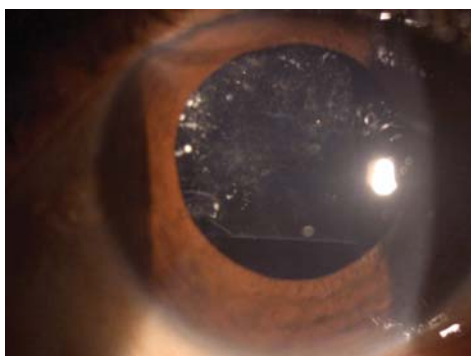


Figure 1: Pre-op photo showing ruptured capsule

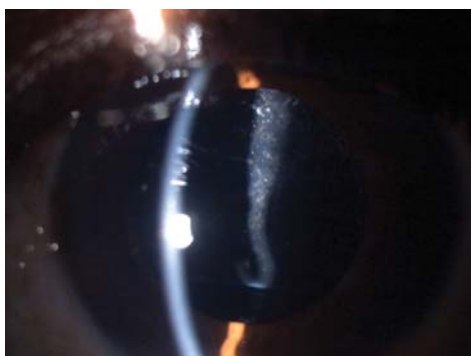

Figure 2: The capsule had rolled up from below



Figure 3: The dislocated hypermature nucleus

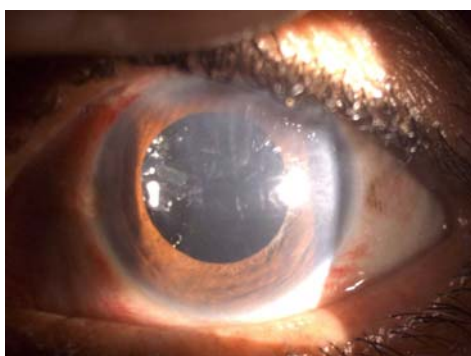


Figure 4: Post op appearance, with IOL in sulcus

No pseudoexfoliative material at the pupillary margin was observed. The fundus was normal. Her intraocular pressure was 12 mm Hg in both

the eyes. A B-scan ultrasound of the left eye showed a flat retina.

Our patient was of normal stature, the cardiovascular and skeletal assessments were normal, and the hearing test results were normal. The patient was advised to have cataract extraction and intraocular lens implantations in the left eye.

She underwent nucleus extraction and IOL implantation in the sulcus and the capsules were left as such (Fig 4). The post-operative vision in the left eye was 6/18 on the first post-operative day.

Discussion

Despite numerous health awareness strategies and campaigns, hypermature cataracts are still frequently seen in our country. Based on our experience, patients' refusal of modern ophthalmic treatment, especially when their fellow eye is seeing well, is the main reason for this situation.

In a hypermature cataract, the milky fluid from the cortical matter flows into the anterior chamber through a minute break in the lens capsule, resulting in anterior uveitis and phacolytic glaucoma. In contrast, a minute break in the posterior capsule may result in gradual absorption of the lens matter without complications. This leaves a hard, shrunken nucleus which may cause the spontaneous dislocation of the lens, especially into the vitreous cavity, and this is attributable to weak zonules.

Spontaneous rupture of the lens capsule in a hypermature cataract is extremely uncommon (Ballen PH et al 1955; Ming AL, 1963). A PubMed search showed that a similar case was reported by Ming in 1963. Ming described the expulsion of the nucleus following rupture of an anterior capsule in a 50-year-old woman who had a hypermature cataract in the left eye; and Ming attributed her poor final visual acuity to an unknown cause of optic atrophy.

Our patient presented with a dislocated nucleus. The presence of multiple calcified spots was indicated by the lens-capsule remnants visible at the eye's pupillary edge. This suggested that a hypermature cataract was the most likely cause of our patient's ruptured anterior lens capsules. The dislocated nucleus was suspended in the posterior chamber just behind the iris.

We postulated that the cortical matter had probably been absorbed much earlier or that there had been a posterior leak into the vitreous cavity. Our patient was asymptomatic, and did not show any sign of lens-induced uveitis or increased intraocular pressure.

It is quite alarming that our patient, a 50-year-old woman, had developed hypermature cataract. There were no systemic signs or metabolic abnormalities to explain her ocular condition. We did not perform a genetic work-up due to her financial constraints.

Spontaneous rupture of the anterior lens capsules has also been described in younger patients with chronic uveitis (Allen JC,1969), polar cataract (Ashraf H et al2008) and other systemic illnesses, such as Alport syndrome (Olitsky SE et al1999; Gupta A et al2011) and Marshall syndrome (Endo S,1998). A complete systemic assessment and genetic work-up are essential when a systemic disease is suspected, especially when nephritis (in Alport syndrome) and connective tissue disease (in Marshall syndrome) are encountered.

Conclusion

A spontaneous rupture of the anterior capsule is sometimes misleading when it occurs in younger and pre-senile age groups. Spontaneous rupture of the anterior lens capsule that leads to dislocation of the nucleus is a rare complication of hypermature cataracts.

References

- Allen JC, De Venecia G. (1969) Spontaneous lens capsule rupture with uveitis. *Am J Ophthalmol.*;67(1):144–149.
- Ashraf H, Khalili MR, Salouti R. (2008). Bilateral spontaneous rupture of posterior

capsule in posterior polar cataract. *Clin Experiment Ophthalmol.*36(8):798–800.

Ballen PH, Hughes WL. (1955) Spontaneous rupture of lens capsule in hypermature (morgagnian type) cataract. *Am J Ophthalmol.*;39(3):403–405.

Bass LJ, Potter JW. (1985) A case of spontaneous dislocated lenses. *Am J Optom Physiol Opt.*;62(5):352–356.

Endo S, Hashimoto Y, Ishida N, Kusano Y, Ohkoshi K, Yamaguchi T. (1998) A case of Marshall syndrome with secondary glaucoma due to spontaneous rupture of the lens capsule. *Nihon Ganka Gakkai Zasshi.*102(1):75–79.

Gupta A, Ramesh Babu K, Srinivasan R, Mohanty D. (2011) Clear lens extraction in Alport syndrome with combined anterior and posterior lenticonus or ruptured anterior lens capsule. *J Cataract Refract Surg.*;37(11):2075–2078.

Haymet BT. (1990) Removal of a dislocated hypermature lens from the posterior vitreous. *Aust N Z J Ophthalmol.*;18(1):103–106

Ho SF, Ahmed S, Zaman AG. (2007) Spontaneous dislocation of posterior polar cataract. *J Cataract Refract Surg.*;33(8):1471–1473.

Ming AL. (1963) Spontaneous rupture of the anterior capsule of a hypermature lens. *Singapore Med J.*;3:127–130.

Mohan M, Bartholomew RS. (1999). Spontaneous absorption of a cataractous lens. *Acta Ophthalmol Scand.*;77(4):476–477.

Olitsky SE, Waz WR, Wilson ME. (1999) Rupture of the anterior lens capsule in Alport syndrome. *JAAPOS.*;3(6):381–382.

Uemura A, Sameshima M, Nakao K. (1988). Complications of hypermature cataract: spontaneous absorption of lens material and phacolytic glaucoma-associated retinal perivasculitis. *Jpn J Ophthalmol.*;32(1):35–40.

Wilson ME, Jr, Trivedi RH, Biber JM, Golub R. (2006) Anterior capsule rupture and subsequent cataract formation in Alport syndrome. *JAAPOS.*10(2):182–183.

Source of support: nil. Conflict of interest: none